

# Difficult Case - AB

July 19, 2018

# History

- 58 y.o. RHD F with worse R shoulder pain over 8 months. Shoulder issues began in 2011 when she fell off a ladder but never saw anyone for it. 2 years later she saw a local orthopedist who obtained an MRI which showed a full-thickness retracted supraspinatus tear.
- 2013 – Outside orthopedist did DCR, SAD and cuff debridement. She got great relief from the surgery and maintained basically normal use of her shoulder until eight months ago when the pain worsened slowly.
- Pain – 8/10
- 04-2018: given subacromial steroid injection with good relief
- 05-2018: Appears to have auto-tenotomized proximal biceps with pain relief
- 07-2018: Pain returned and function worsened

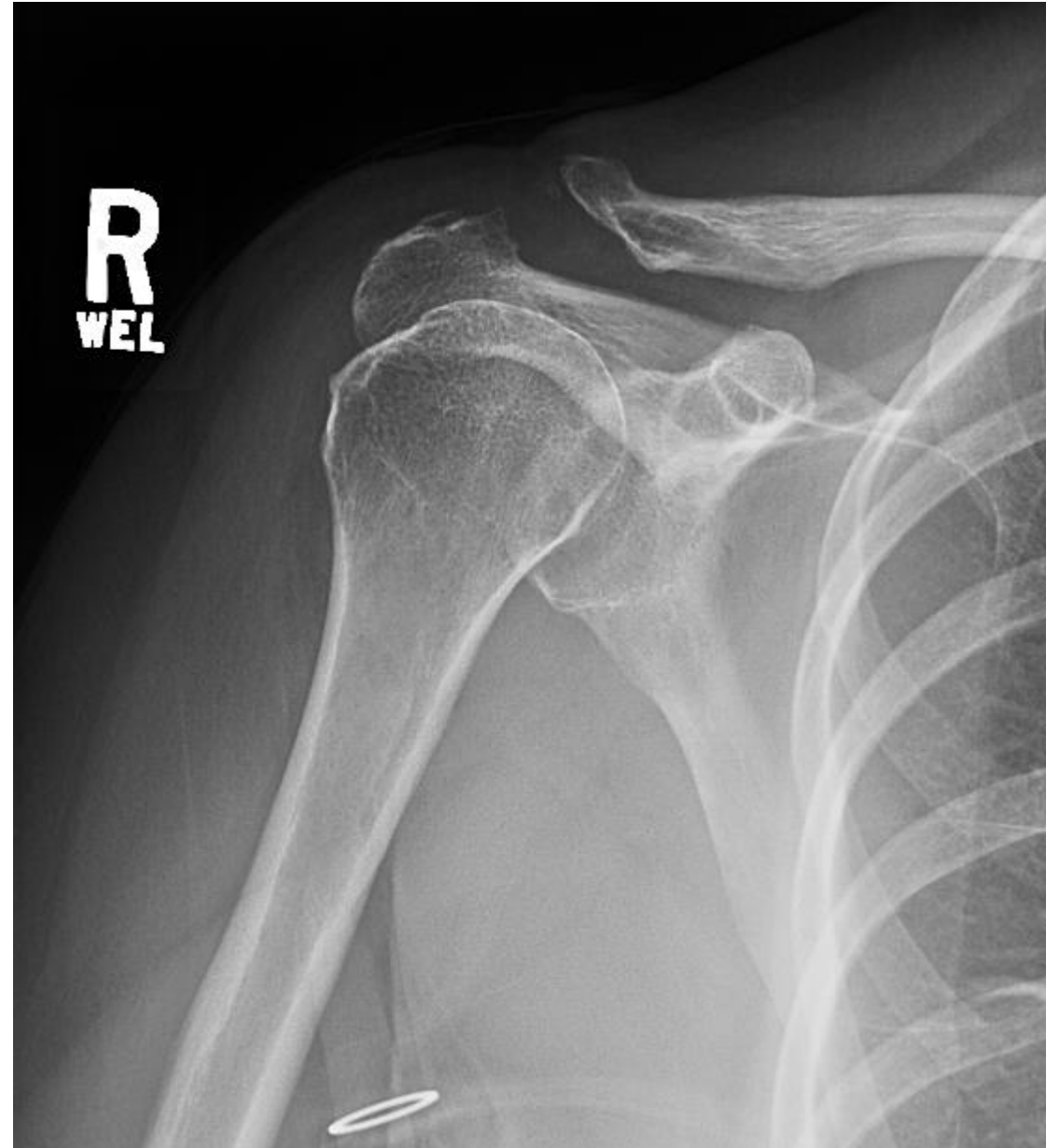
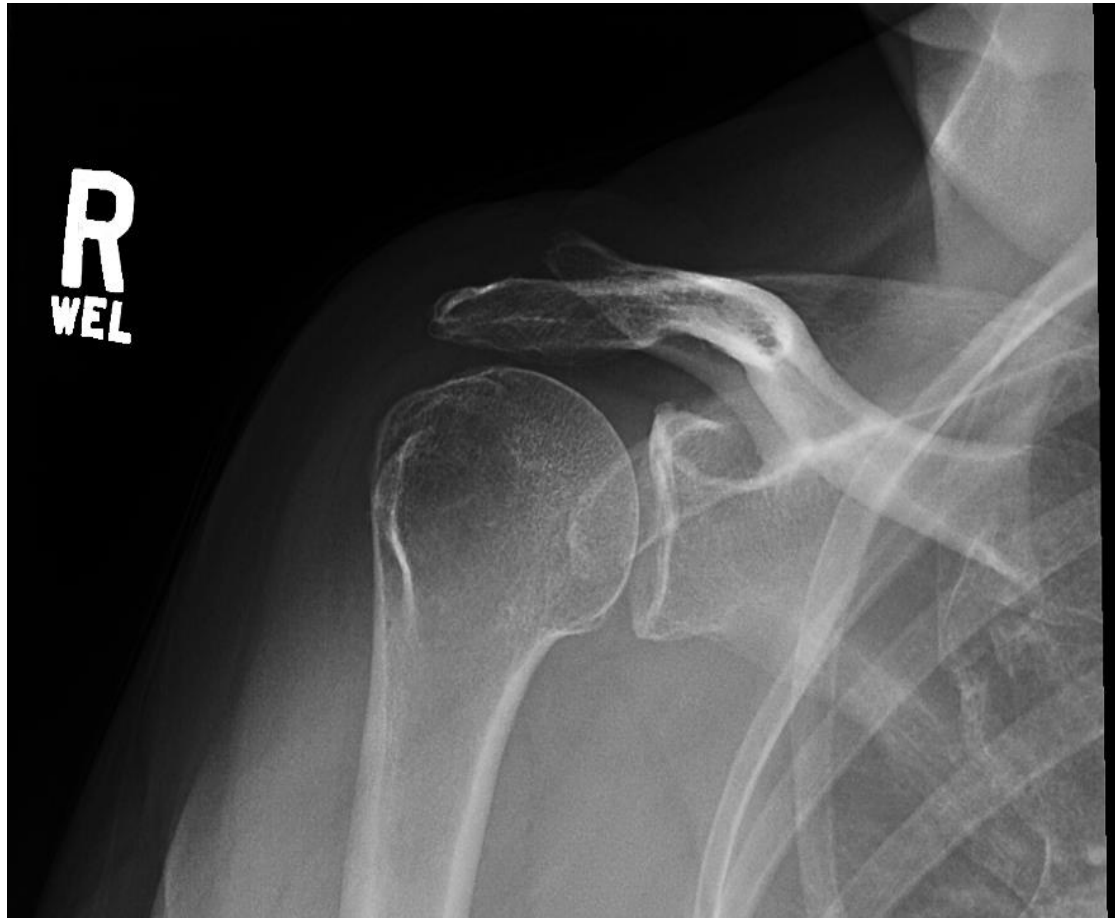# Medical History

- PMH: HTN and PE (10 years ago on chronic coumadin)
- PSH: Foot surgery and noted shoulder surgery
- Meds: Omeprazole, diovan, simvastatin, warfarin, meloxicam
- ALLERGIES: NKDA
- SH: No tobacco, alcohol or drugs. Self-employed daycare owner and chocolatier

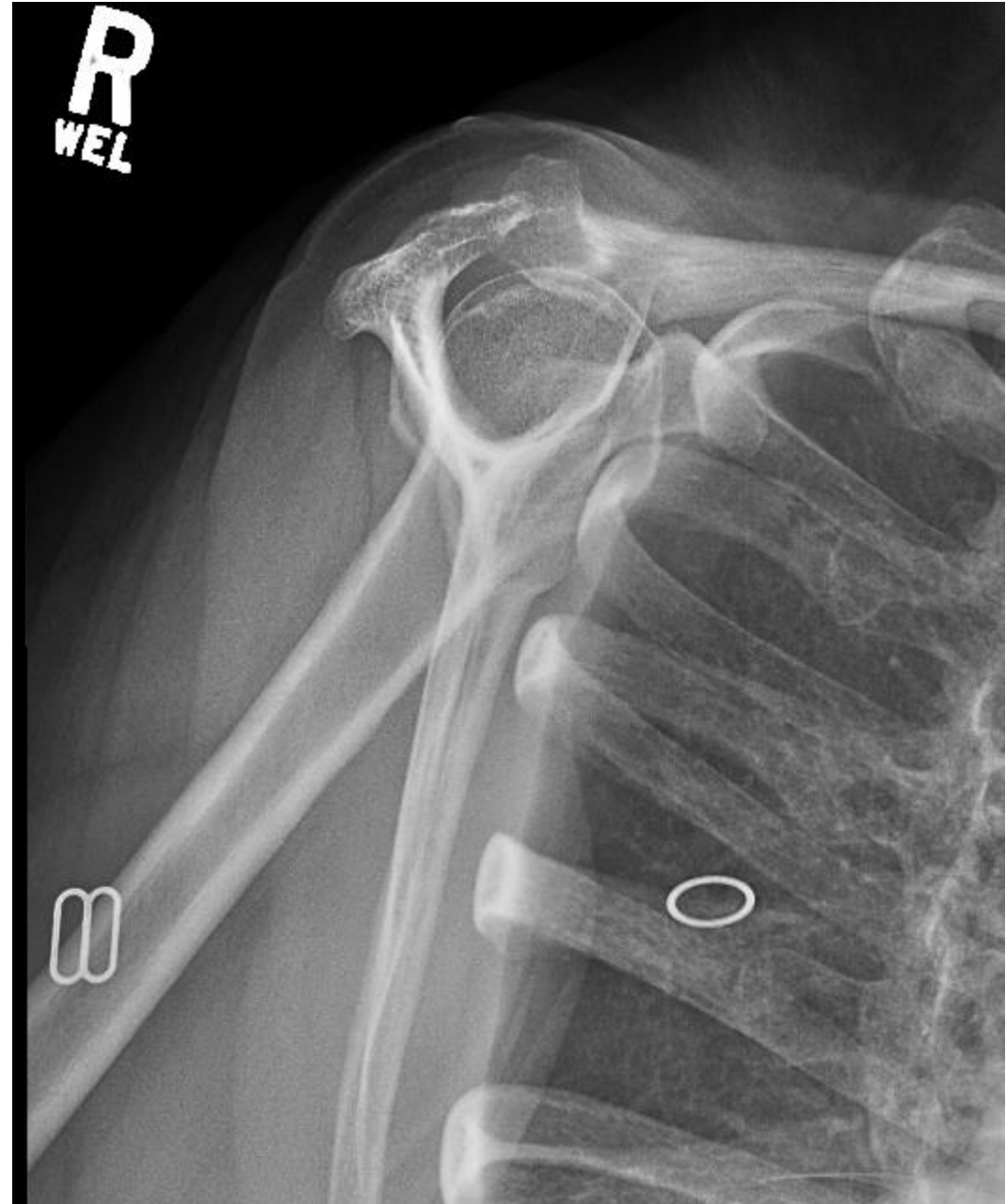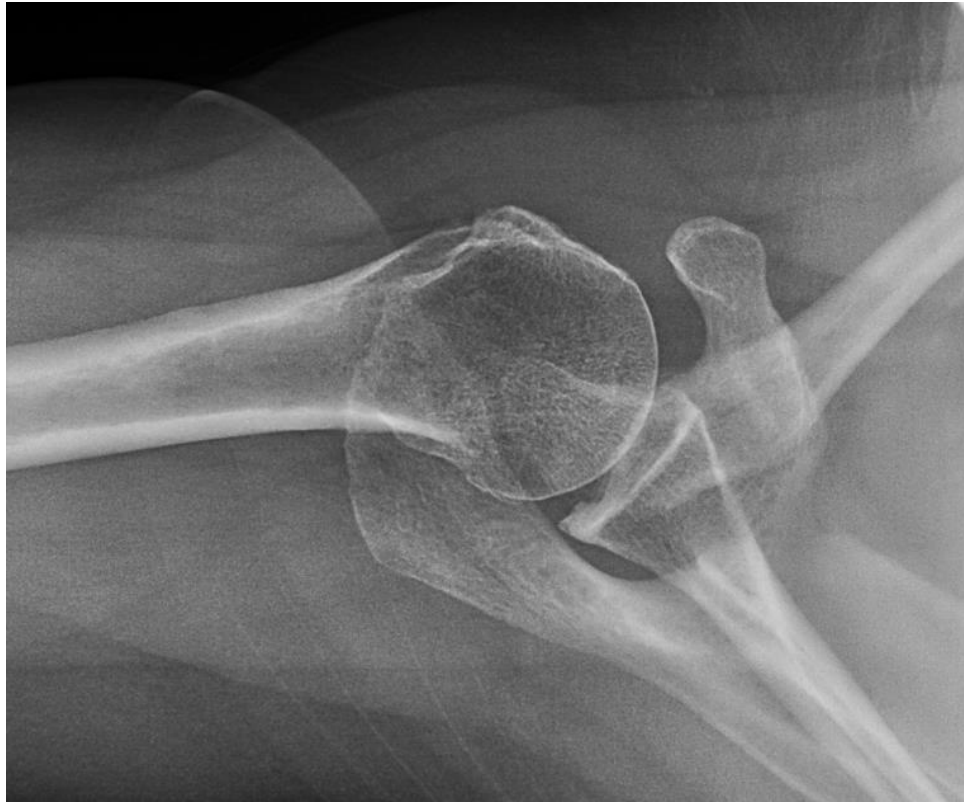
# Exam

- 5'3" 170 lb
- At presentation in April, 2018 she had FE 150, ER 45, and IR T12
- Physical exam July, 2018
- Right upper extremity:
  - AFE 70, PFE 160 (L – AFE 160)
  - AER 45 (symmetric)
  - AIR T12 (symmetric)
  - 5/5 strength to ER and IR, 4/5 strength to resisted abduction in scapular plane
  - Evident popeye deformity

# Imaging

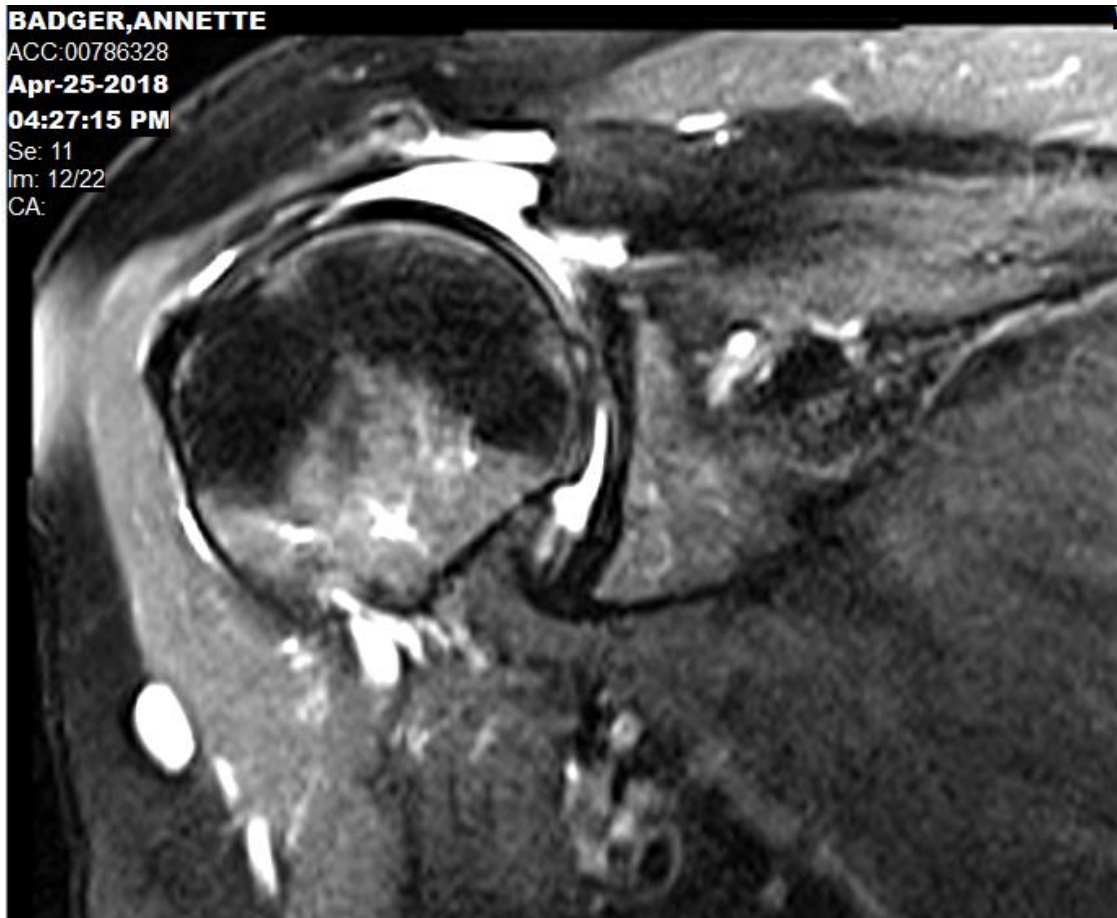

# Images (cont)

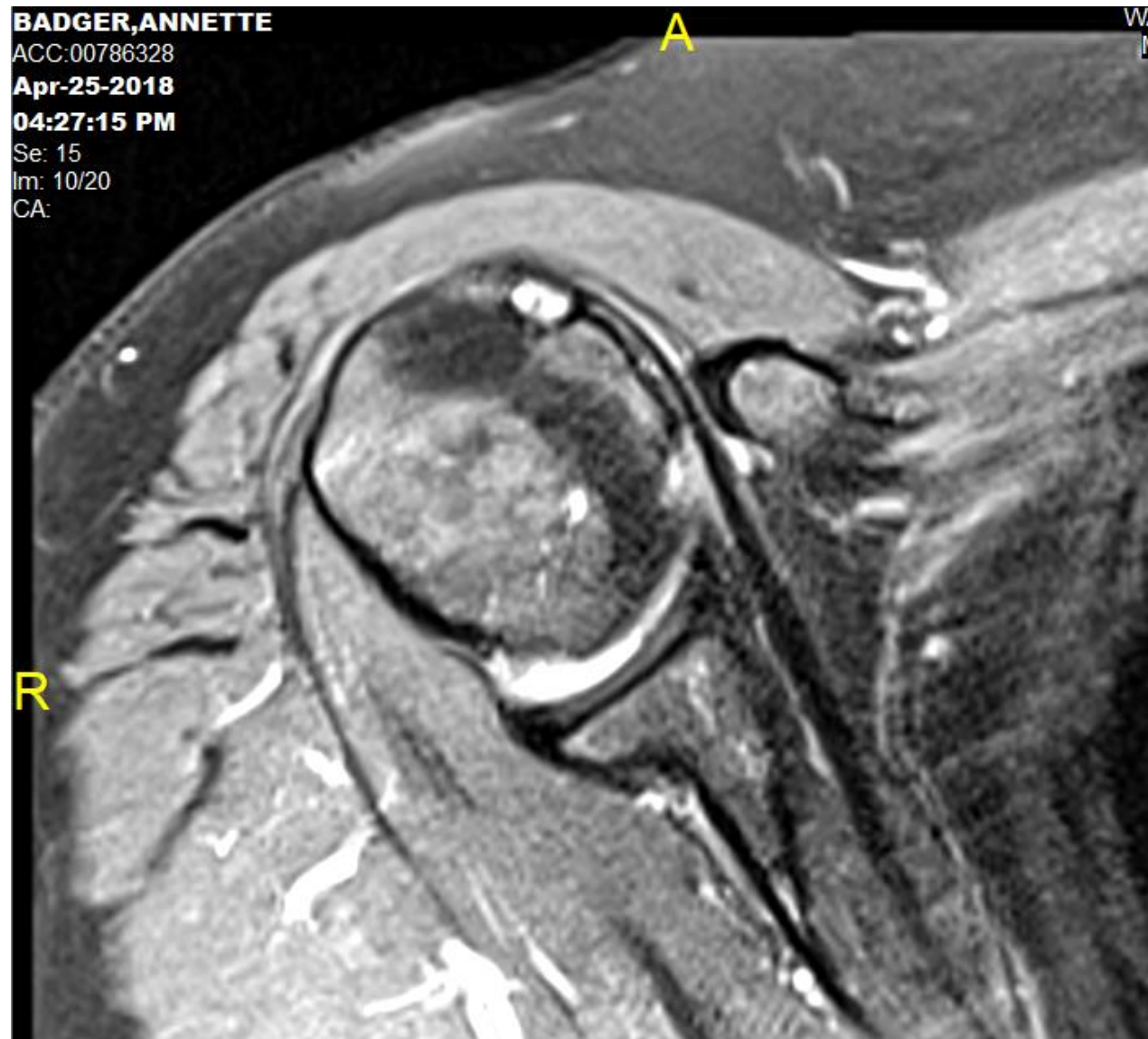

# MRI

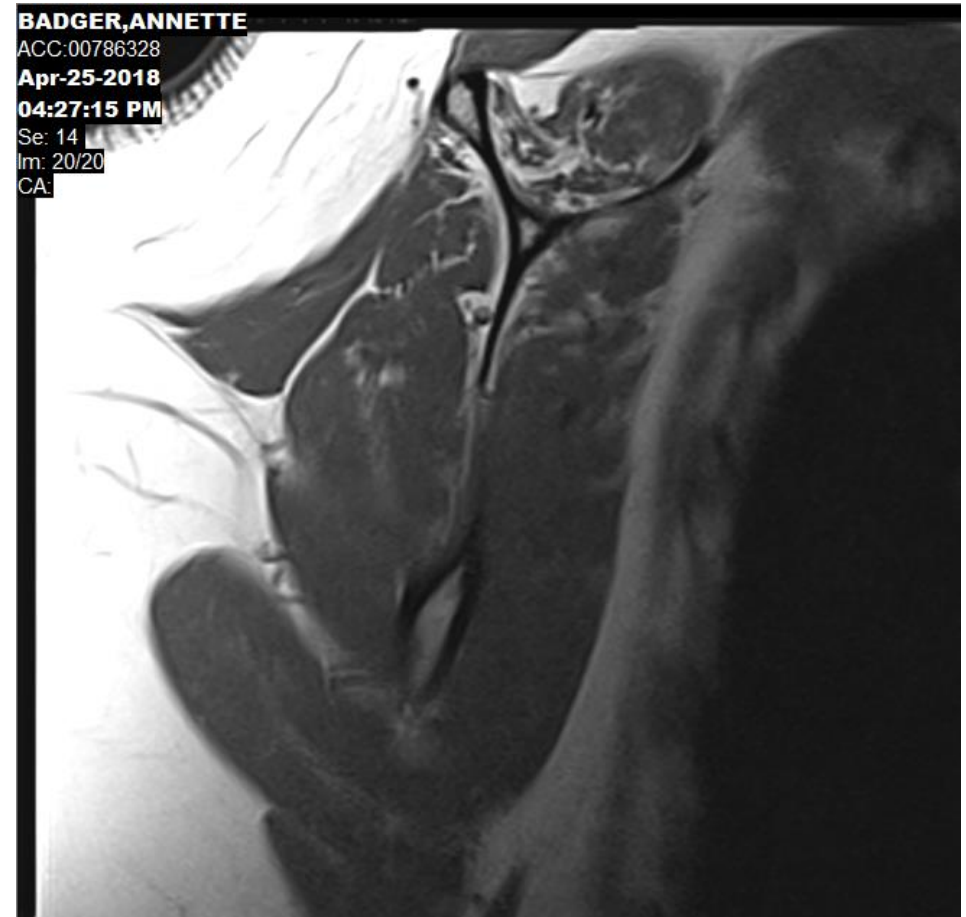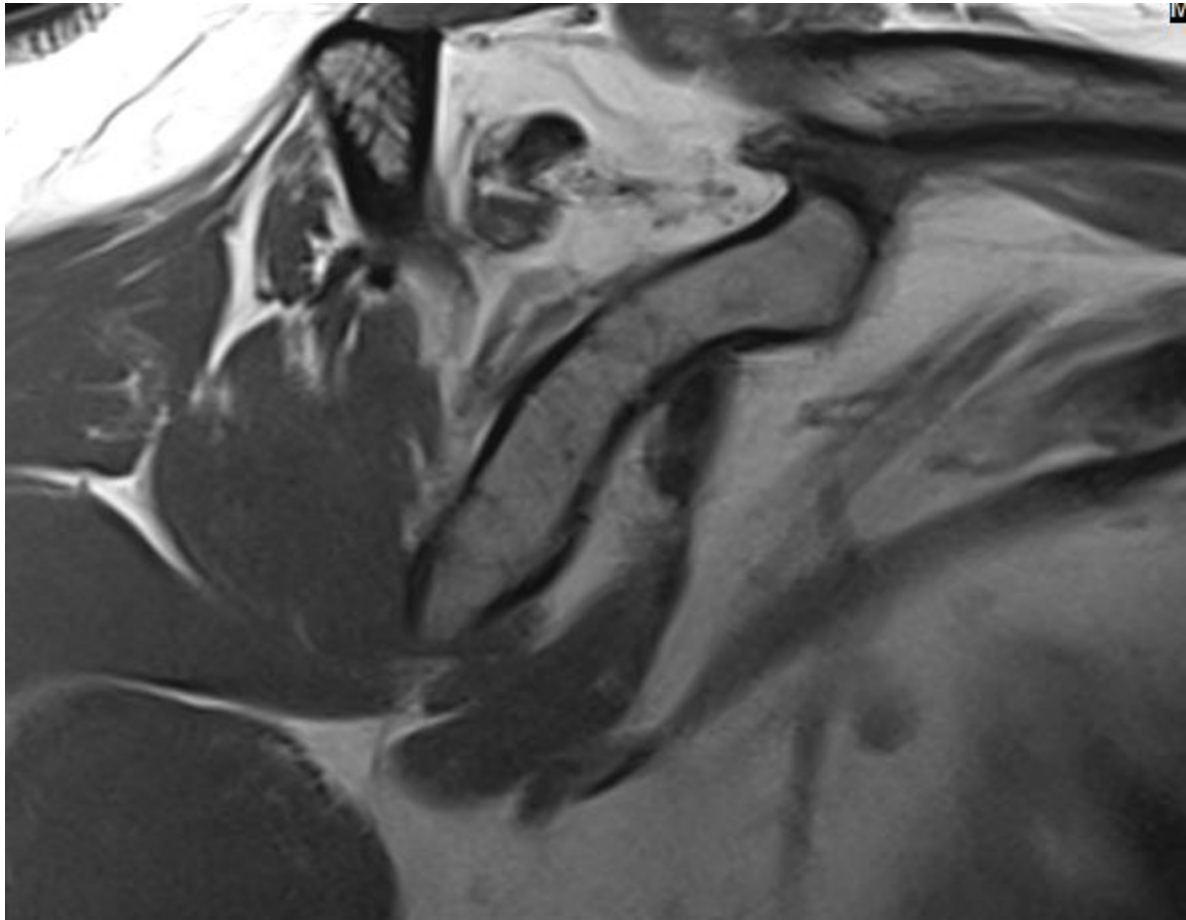
**BADGER,ANNETTE**  
ACC:00786328  
**Apr-25-2018**  
**04:27:15 PM**  
Se: 11  
Im: 12/22  
CA:



**BADGER,ANNETTE**  
ACC:00786328  
**Apr-25-2018**  
**04:27:15 PM**  
Se: 15  
Im: 10/20  
CA:



# MRI (cont)





# What to do?

- 58 y.o. healthy female with minimal arthritis who has developed pseudoparalysis from a chronic supraspinatus tear after losing proximal biceps support.
- SCR?
- Tendon transfer?
- Reverse?