

Codman Case

5/22/18

Patient MRN: 5999030

47 y/o F c shoulder pain + stiffness

- ID: 47 y/o RHD M with LEFT shoulder pain
- HPI: Multiple dislocations since adolescence (unk #)
 - 3 years ago: arthroscopic Bankart at OSH complicated by stiffness requiring arthroscopic capsular release (2.5 years ago), and eventually a MUA (2 years ago) all at OSH
 - Recurrent anterior dislocations after MUA
 - 1 year ago: Latarjet by Dr. Warner, complicated by recurrent stiffness requiring an global arthroscopic/open capsular release + BP dissection
 - Continues to have stiffness and pain, but no recurrent instability despite extensive PT
 - Pain 1-4/10, SSV 50%
- PMHx: Healthy
- Meds: None
- Allergies: PCN
- SH: Non-smoker; Limited Alcohol use

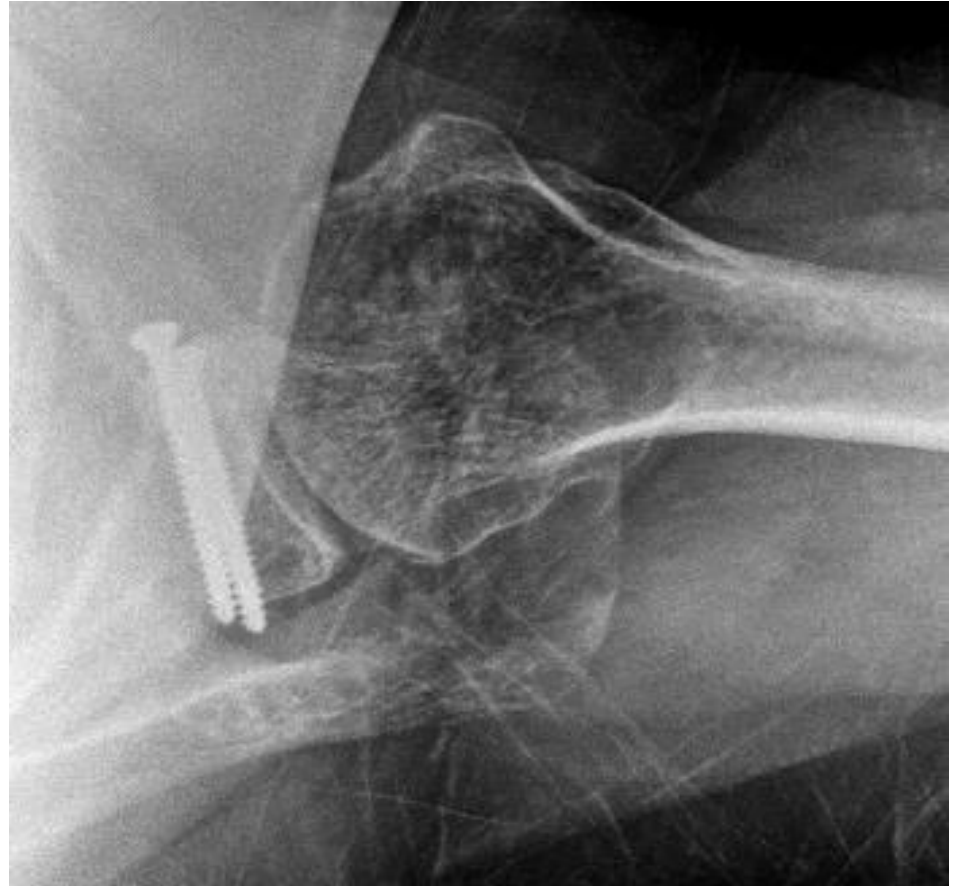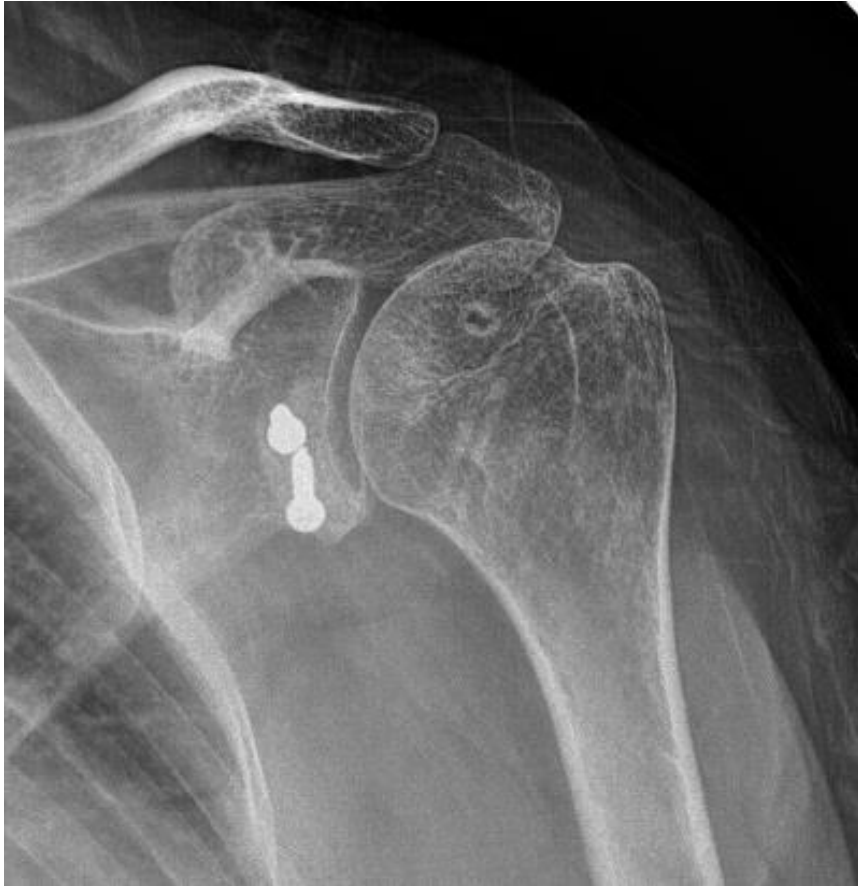47 y/o F c shoulder pain + stiffness

■ Physical Exam:

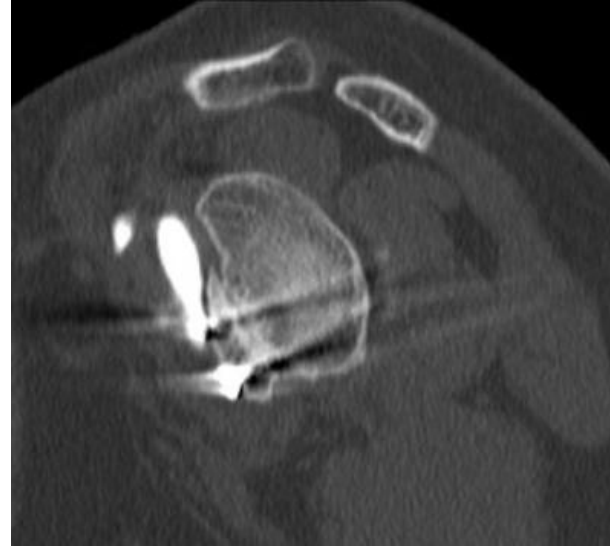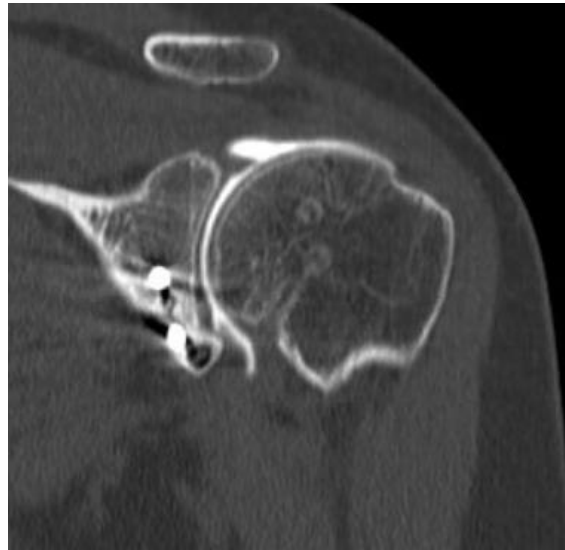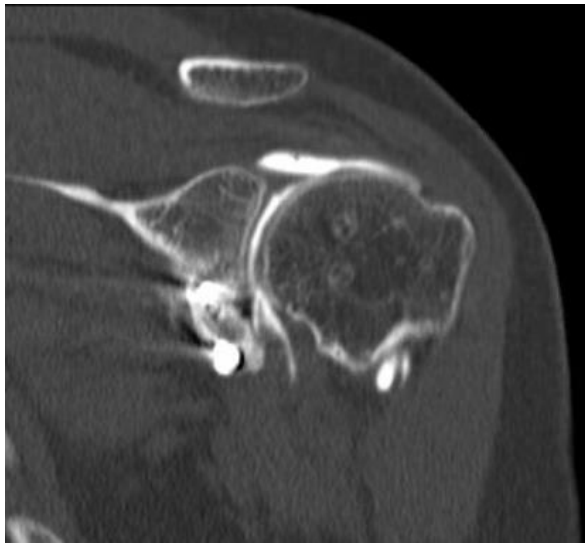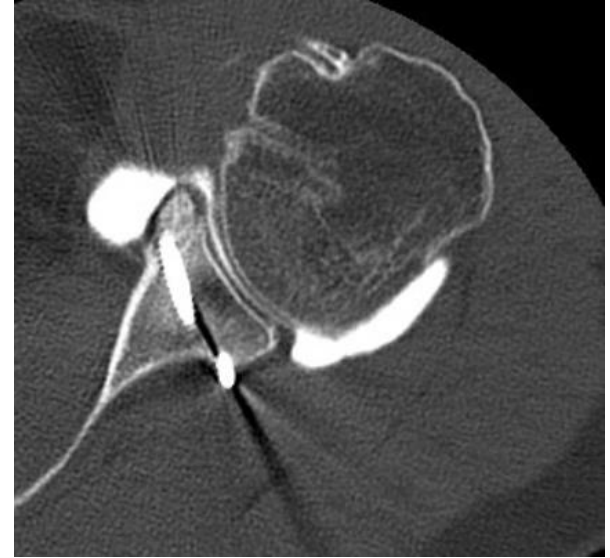
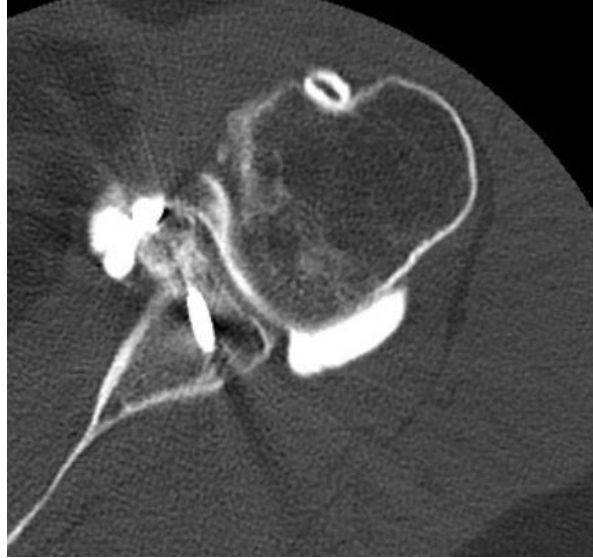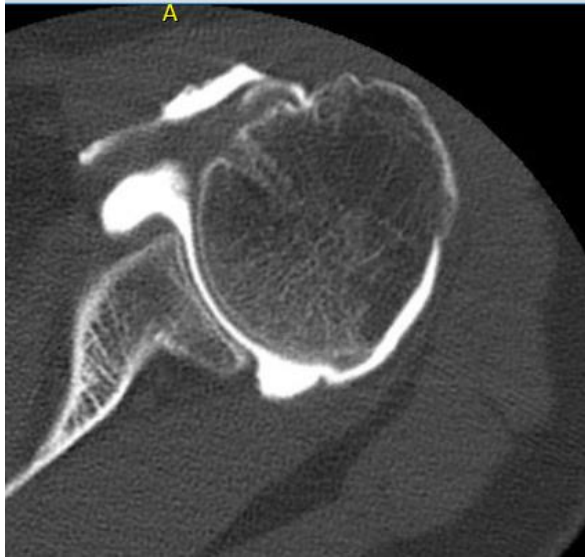• AROM/PROM

- FF: 110/140 (160 R)
- ABD: 90/110 (140 R)
- ER: 0/0 (60 R)
- IR: PSIS (L1 R)
- Abd ER at 90 deg: 40/40 (90 R)
- Abd IR at 90 deg: 10/10 (90 R)
- Strength: 4/5 ABD, 5/5 ER and 5/5 IR
- Subscapularis intact (neg bear hug, belly press)
- NVI (including axillary)

47 y/o F c shoulder pain + stiffness



47 y/o F c shoulder pain + stiffness



47 y/o F c shoulder pain + stiffness

- ID: 47 y/o F s/p multiple procedures
 - Bankart → capsular release → MUA at OSH
 - Latarjet → arthroscopic/open capsular release
 - Stiffness in ER and IR + pain

- Recommendations???