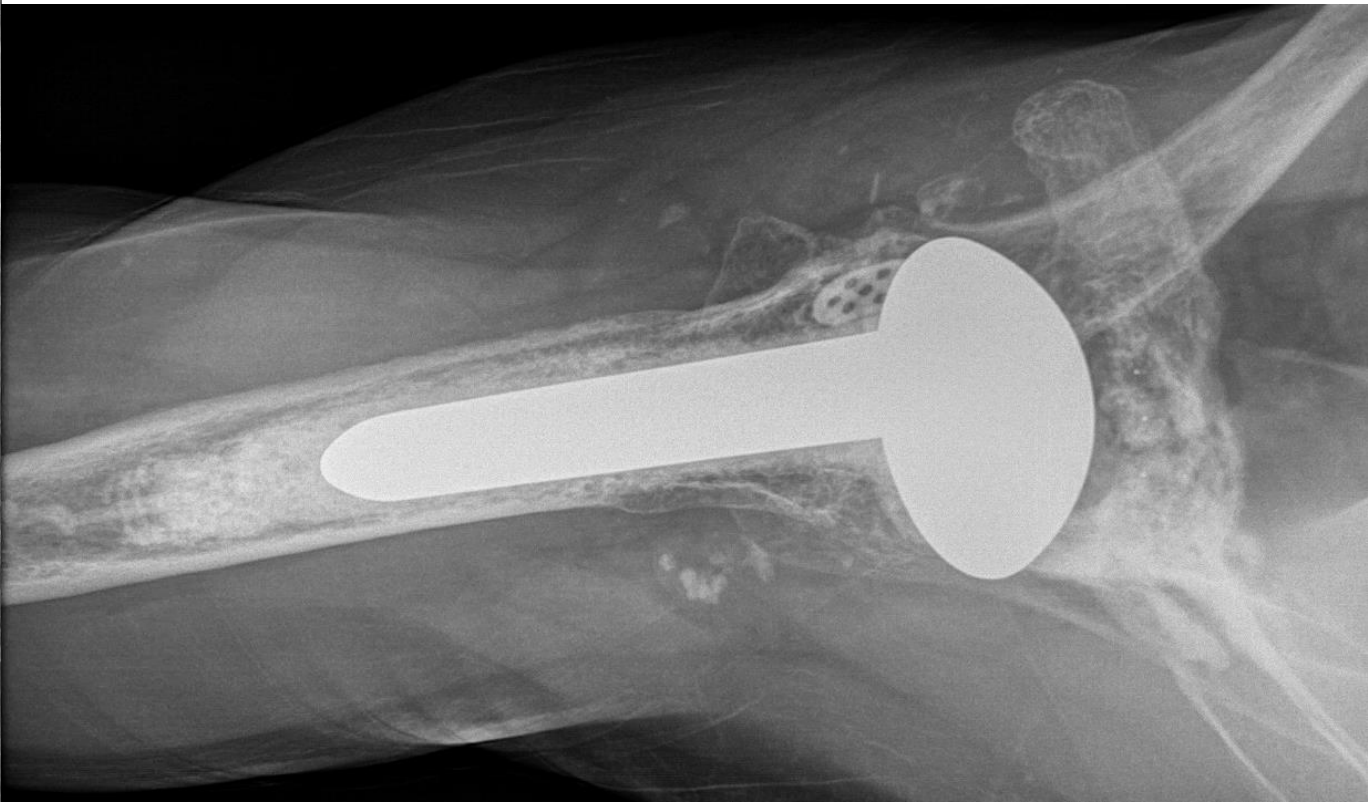
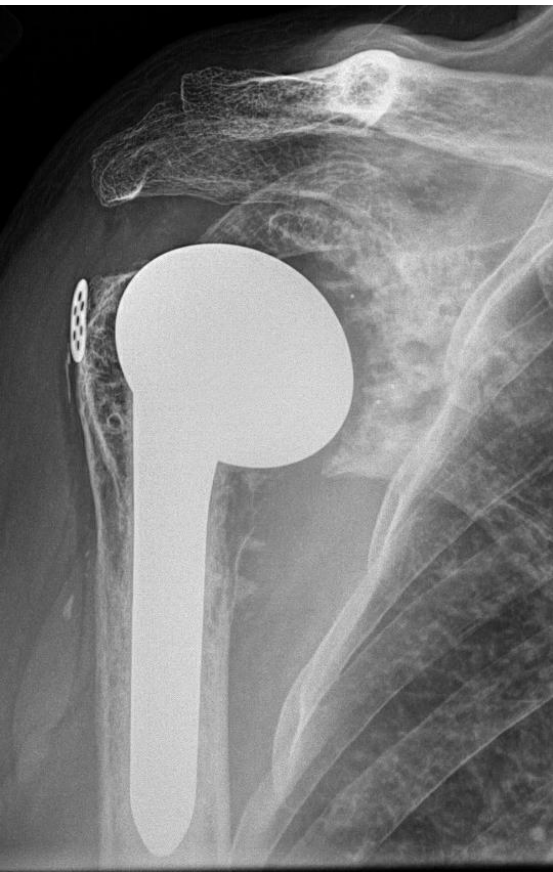

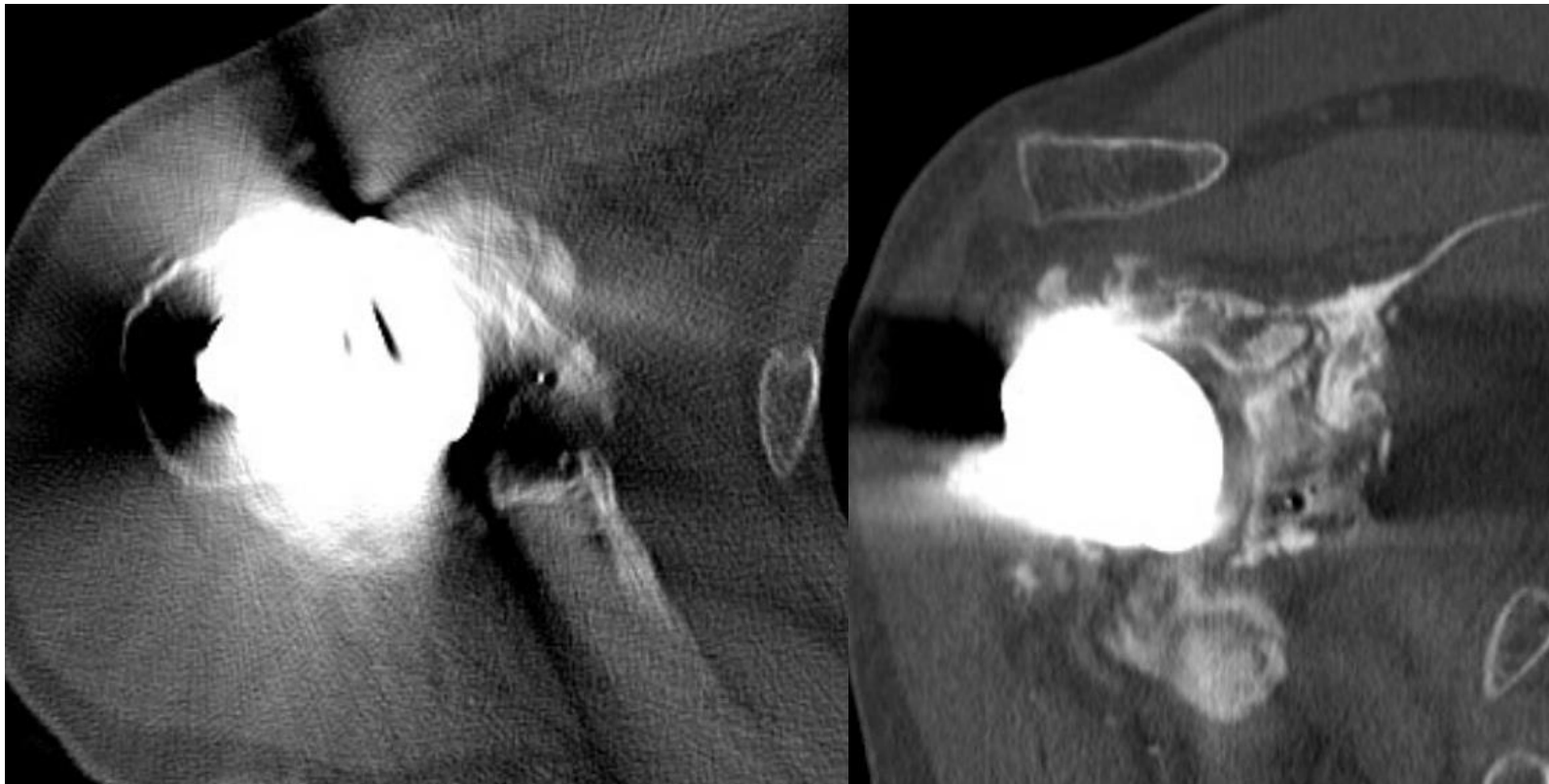
# Patient RP

- 73 yo RHD male with history of painful RIGHT TSA (performed by Dr. Warner in 2003)
- Recently had a painful LEFT TSA converted to RSA in August 2017 and is very happy
- RIGHT TSA did well for about 13 years until developed progressively worsening pain
- Underwent surgery December 2017 with plan for RIGHT conversion to RSA but procedure aborted due to significant glenoid bone loss
  - Monoblock stem required stem removal
  - Significant pseudotumor formation with metallosis present
  - Severe glenoid bone loss involving almost entire glenoid vault, precluding any reconstruction at that time
- OR cultures: negative

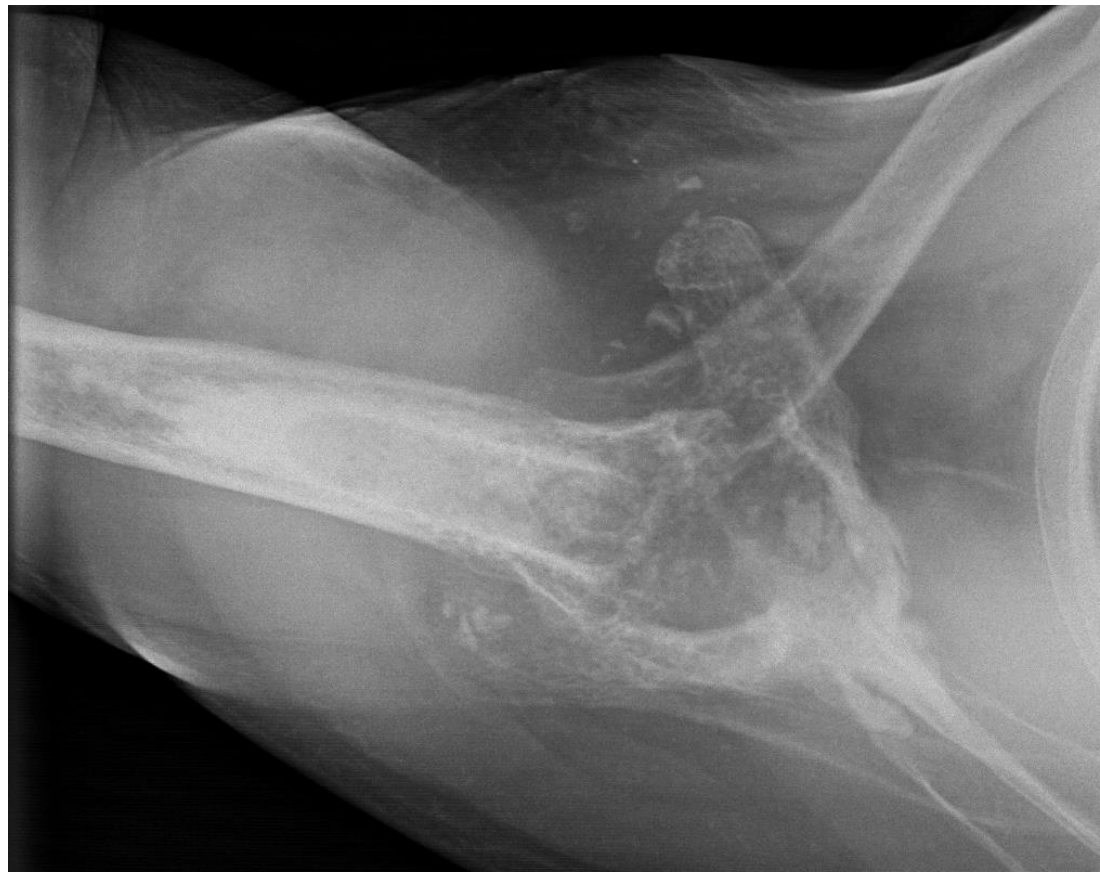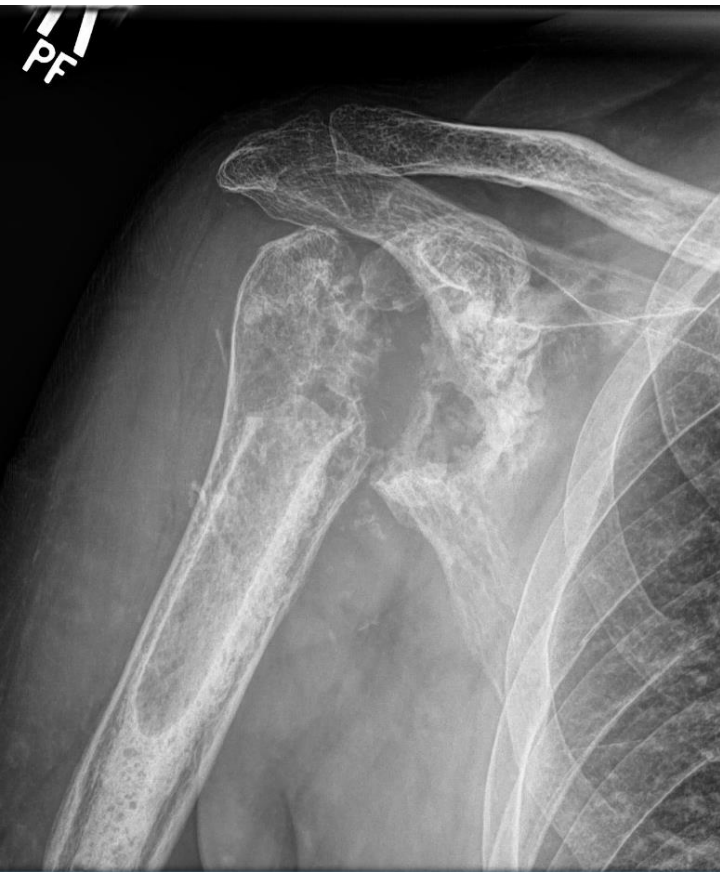# Pre-operative Images



# Pre-operative Images

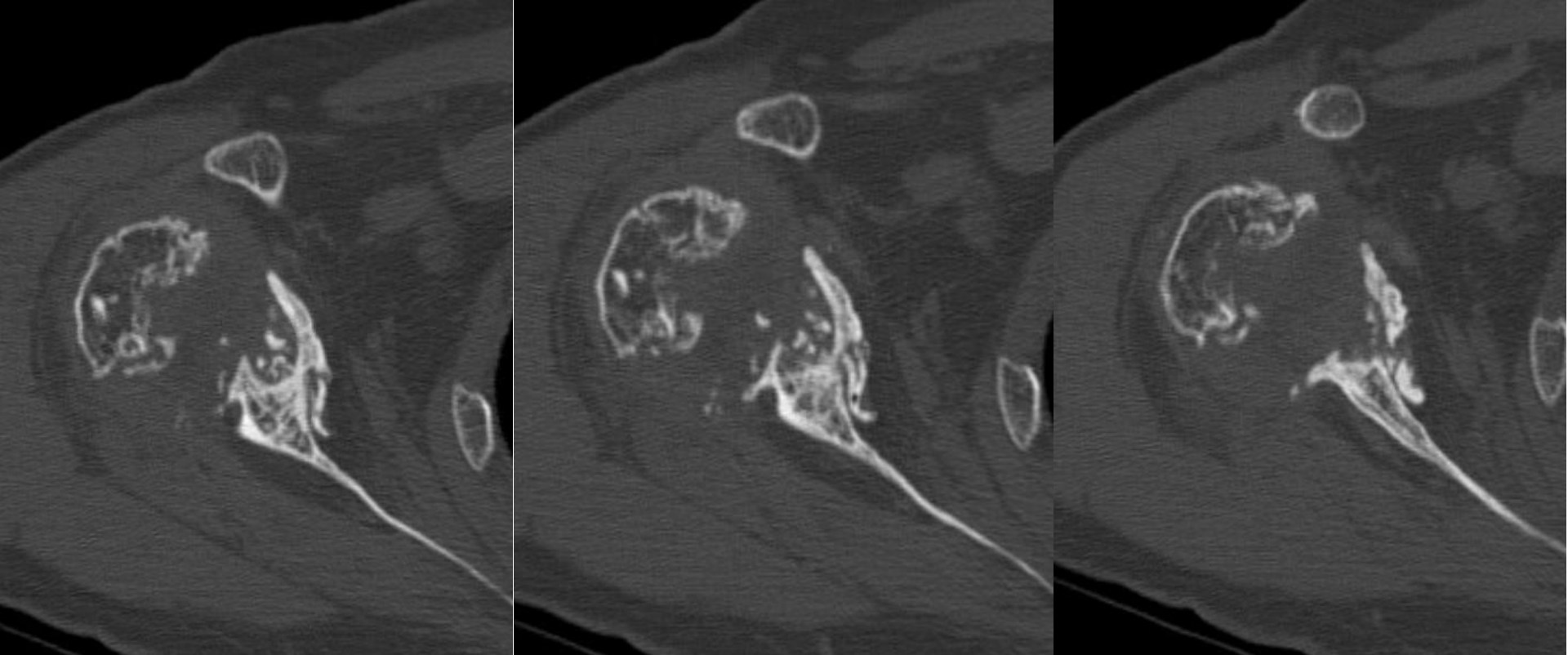


## Post-operative Images

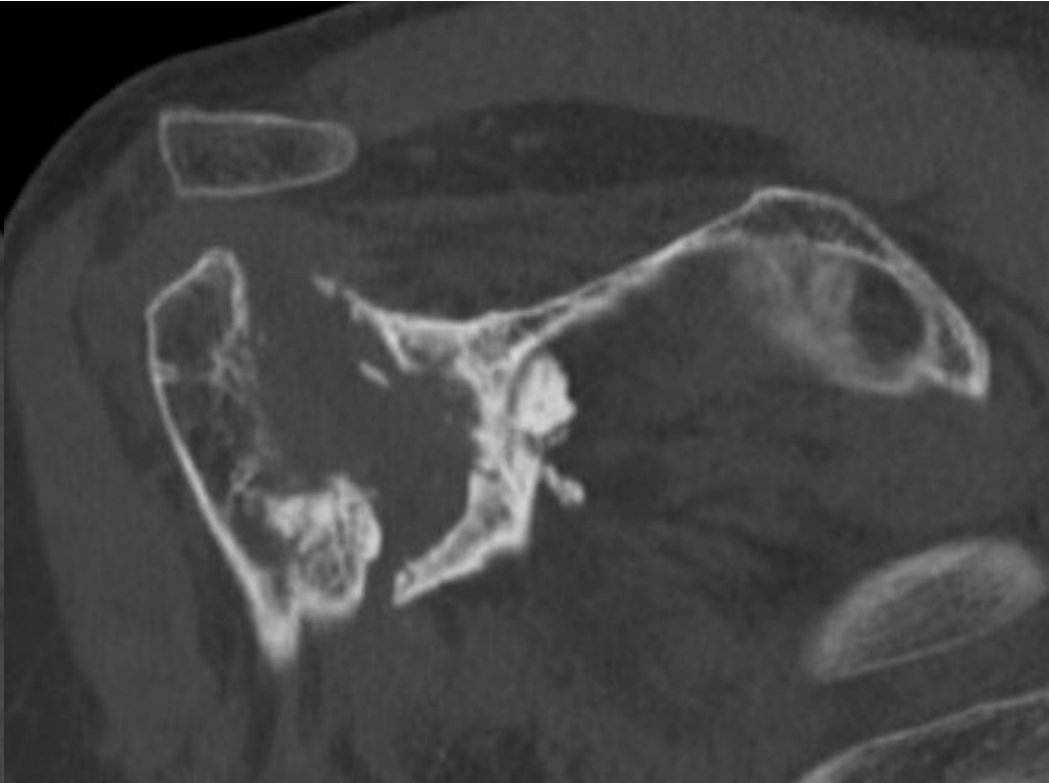
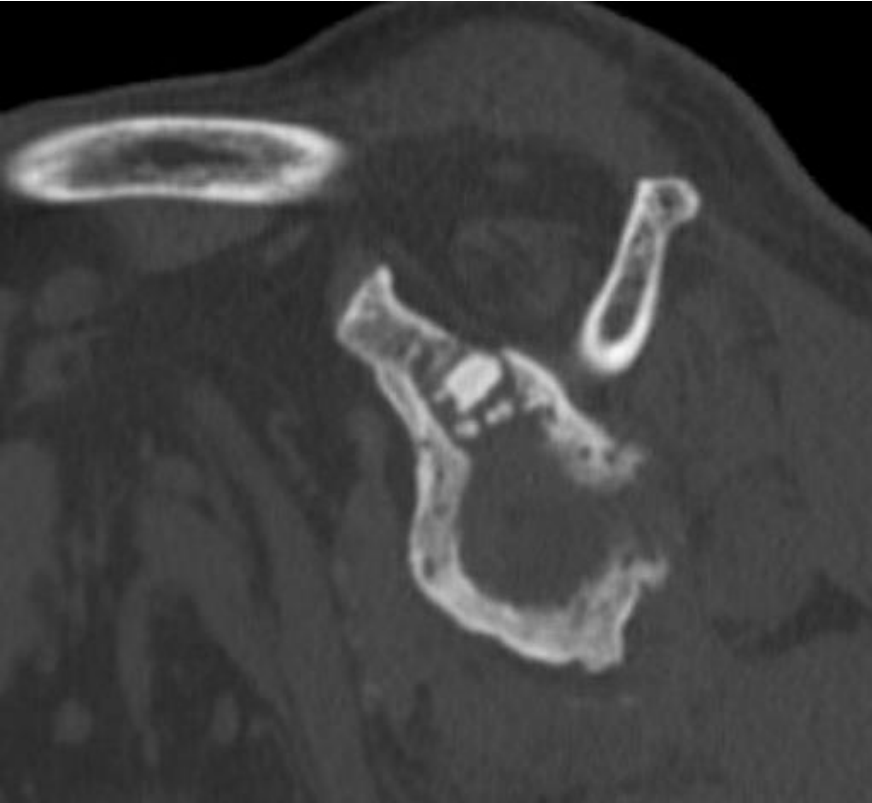


- Patient initially did well after resection arthroplasty with only minimal pain; noted to have good motion with ability to place hand on head 2 months post-op
- Patient now complaining of progressively worsening pain
- Pain ranges from 9-10/10; SSV 25%
  
- Physical Exam
  - RIGHT Upper Extremity
    - Well healed incision
    - AROM:
      - FE to 90 degrees, can place hand on head
      - ER 20 degrees
      - IR to PSIS
    - Neurovascularly intact

# Post-operative Images



# Post-operative Images







#### OPTIONS?:

1. Revision with Allograft/Autograft
2. 2-stage revision with “ ”
3. Don't do anything
4. Other