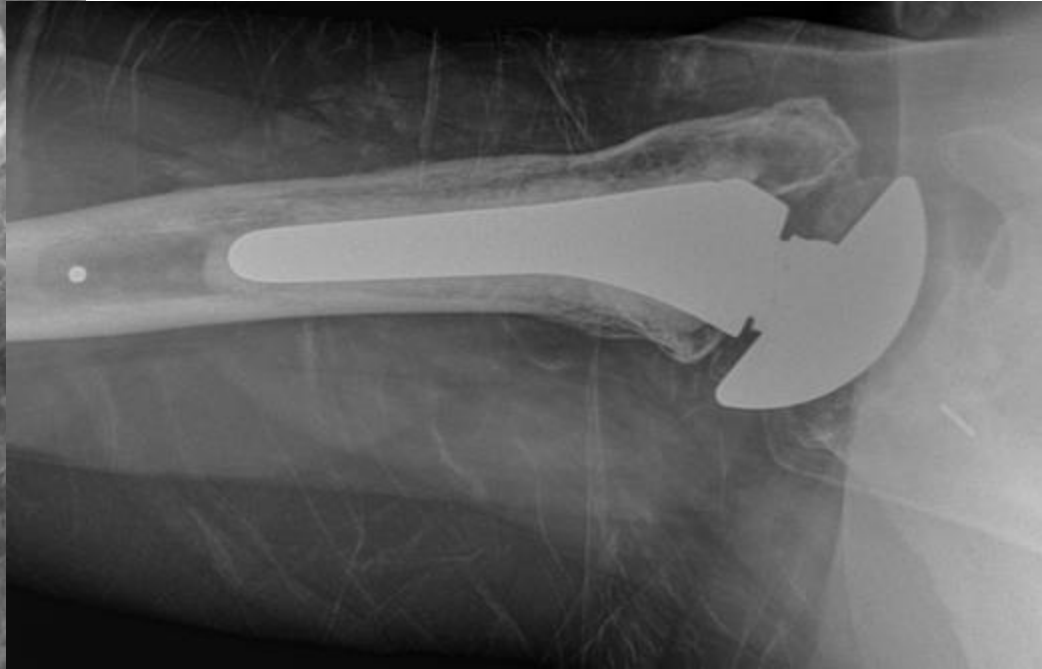
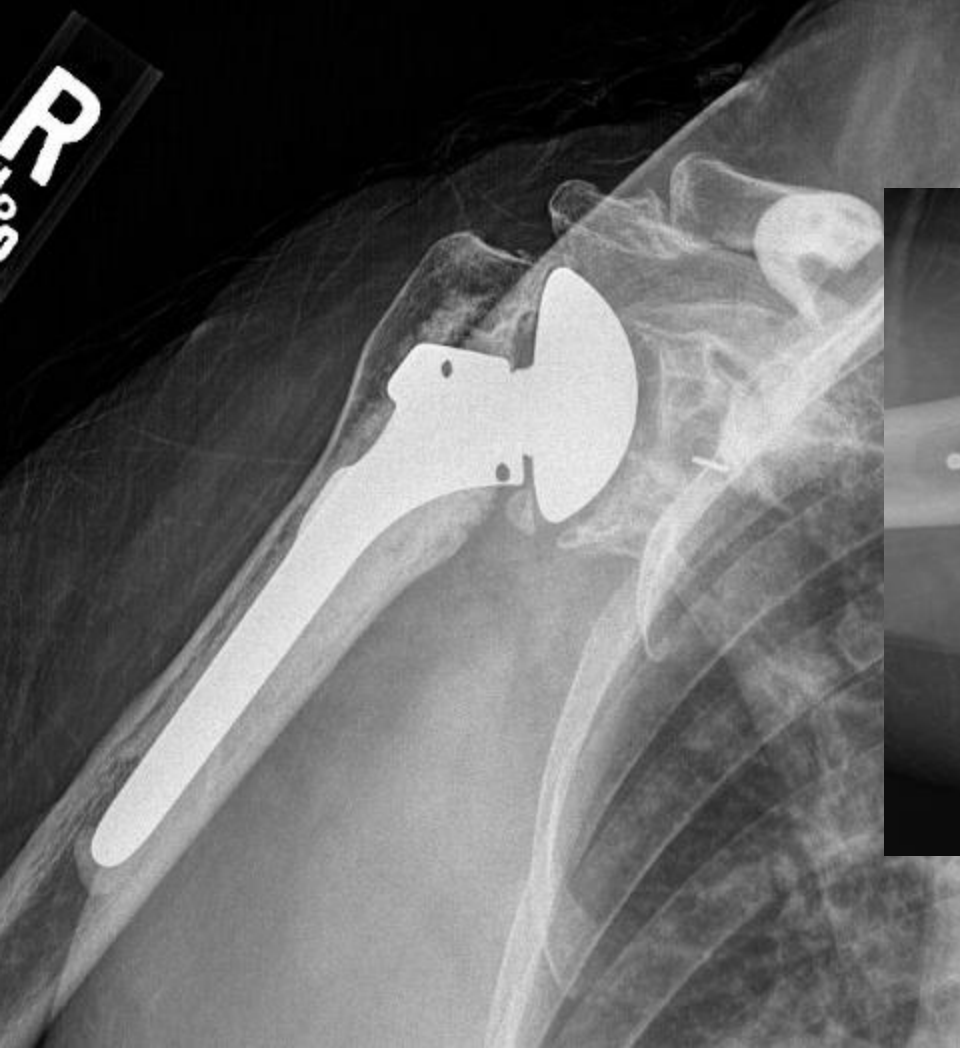
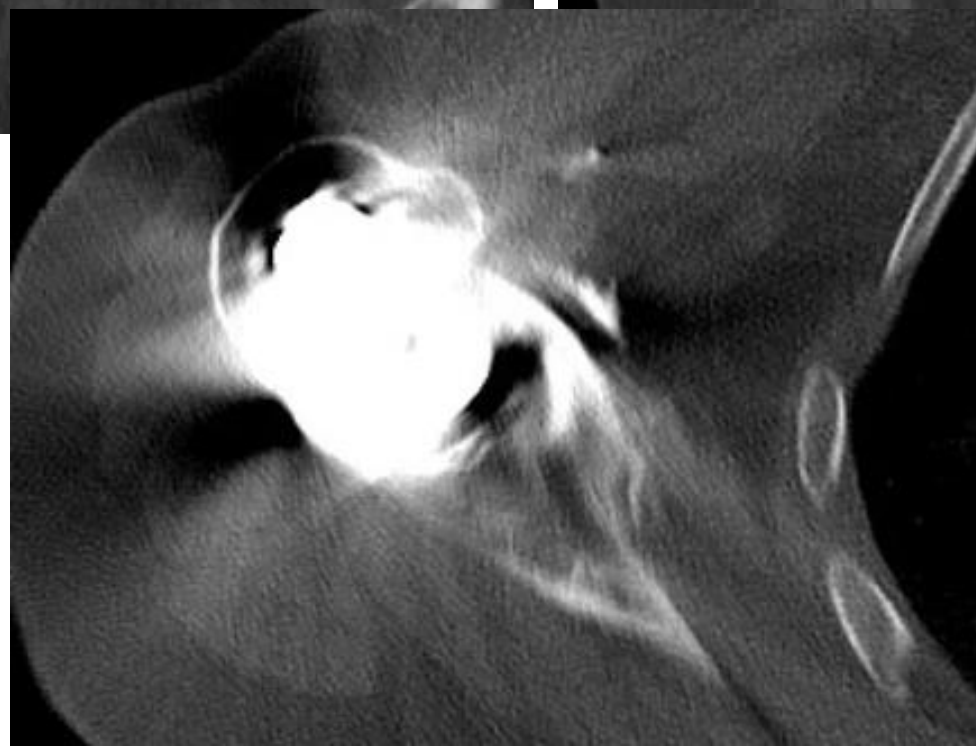
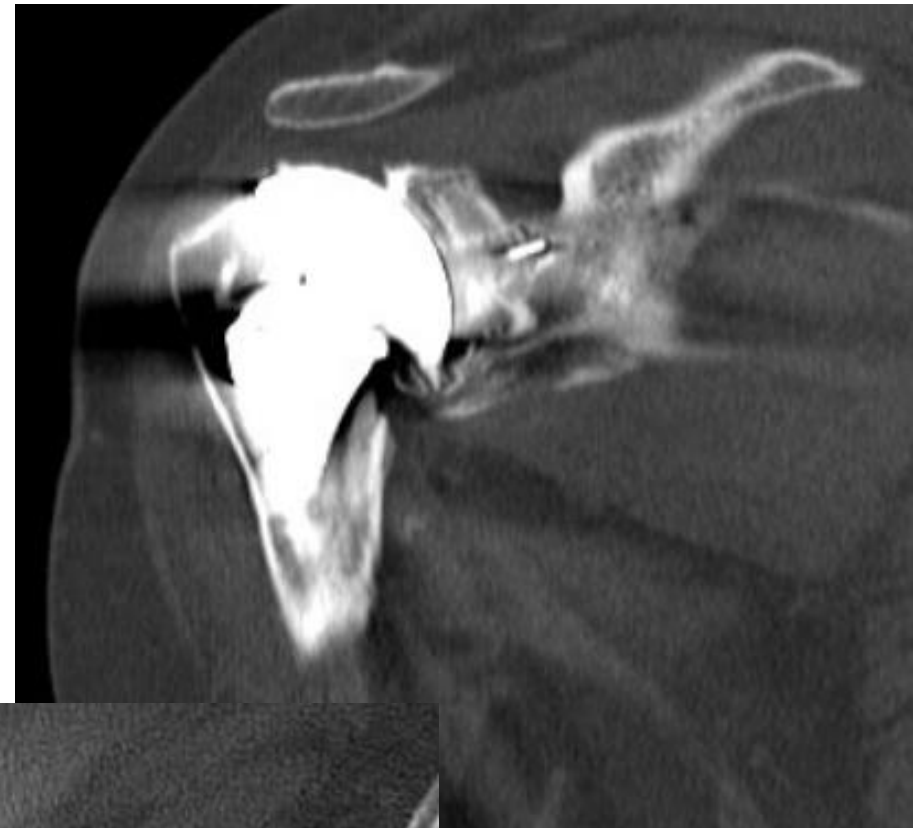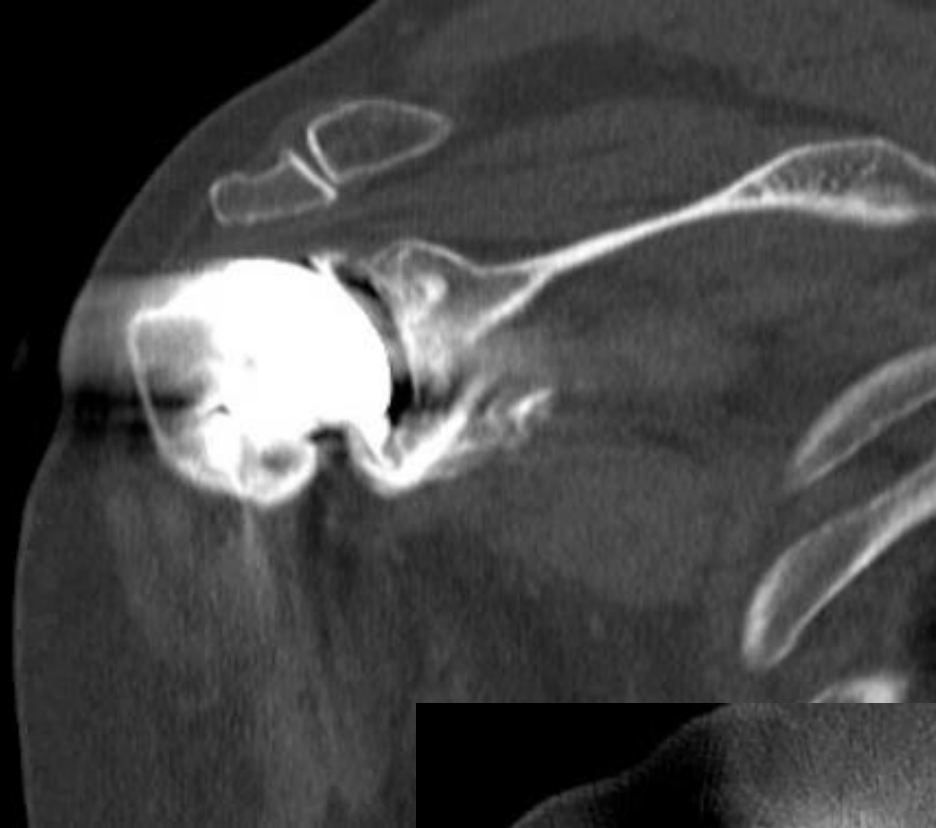


55 y/o F

- ID: 55 yo RHD female with RIGHT shoulder pain and stiffness
- HPI:
 - Pain in shoulder for the past year with following complex shoulder history
 - 2008: Right shoulder arthroscopy (outside hospital)
 - 2011: Complicated right total shoulder arthroplasty (outside hospital)
 - 9/24/2012: Revision loose humeral stem (Dr Warner)
 - 11/19/2013: Right shoulder open capsular release (Dr Warner)
 - 5/21/19: Right shoulder aspiration: culture negative
 - 9/25/2019: Right shoulder arthroscopic biopsy, assess for loosening, possible rotator cuff repair, subacromial decompression
 - Biopsy results: 4 out of 6 biopsies negative, 1 positive for *C. acnes* & 1 positive for *Staph. epidermidis*
 - Pain at rest 3-4 out of 10, pain at worst 10 out of 10, positive night pain, SSV 25%
- PMHx: Depression
- PSHx: Shoulder surgeries listed above
- Meds: Citalopram, multivitamin
- Allergies: NKDA
- SH: Denies tobacco use, EtHO socially





Treatment options:

- Revision to RTSA
- 2 stage exchange